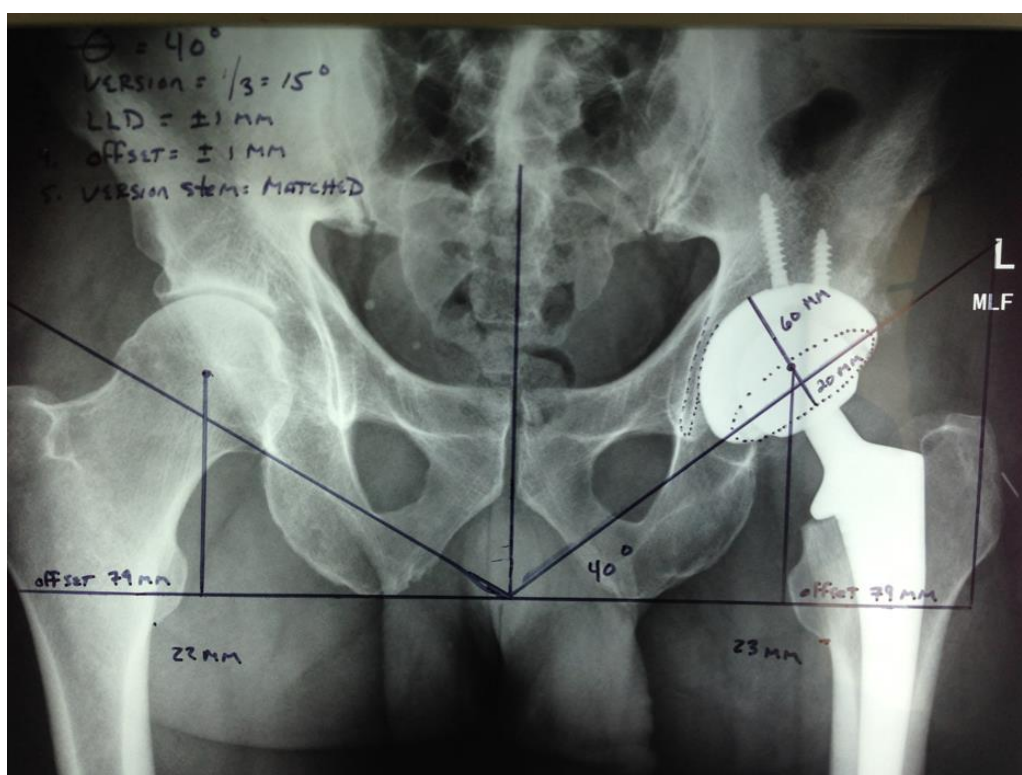


A More Exact Way of Doing Things: Direct Anterior Approach to Hip Replacement



Building a Joint Replacement Center at Mammoth Hospital:
One patient, One team, One Innovation at a Time

Michael M. Karch, MD

Board Certified Orthopaedic Surgeon

Fellow AAOS/ABOS

Although total hip replacement surgery remains one of the most successful operations in orthopedic surgery with regards to patient satisfaction surveys, there are still inherent problems with the traditional surgical approach that may cause problems in the immediate and long term post operative course. Dislocation of the components, leg length discrepancies, pain and loss of power as well as early wear and breakdown of the components requiring revision hip surgery are among the most commonly cited problems with hip replacement surgery. Recently, minimally invasive and tissue sparing procedures have gained attention as patients demand shortened recovery times, accelerated rehabilitation, and a return to a higher level of function.

In an effort to constantly improve surgical outcomes, the Direct Anterior Approach to the hip was introduced to the United States as a way to possibly improve on these outcomes, reduce rehabilitation times and reduce the complications associated with the more traditional approaches to the hip.

Virtually all surgical residents in North America are trained on the traditional posterior or lateral approaches to the hip. Consequently, the vast majority (Greater than 80%) of Orthopaedic Surgeons in the United States today continue to use this traditional approach despite its cited problems. The Direct Anterior Approach was introduced to the United States from Europe as an answer to the above mentioned problems. Currently, about 20% of surgeons have adopted this new approach for some of their hip replacement surgeries and only about 10% have converted to this approach 100% of the time.

Barriers presented to surgeons with regards to learning this new technique are many and can prohibit one from making the change out of their comfort zone of the traditional posterior approach. The new Anterior approach itself is technically more difficult, it requires an extensive learning curve as well as many unpaid hours of reading, learning in cadaver labs, and traveling to centers in the US and Europe to watch this operation being done by those that have mastered it. The new approach also requires the use of a sophisticated operating table that presents a capital expense that may be cost prohibitive to some hospital systems.

Why would surgeons make this extra effort overcome these personal, professional and financial barriers in order to learn a new approach to the hip? To those who have already made the leap, the answer is very clear: The outcomes are clearly better for their patients and a new, higher level of performance outcome can be achieved. This is especially true in patients that place physically high demands on their hip such as those cyclist, climbers, skiers, ranchers, workers and mountaineers found in the Eastern Sierra.

In 2006, I had the unique opportunity to learn the Direct Anterior Approach from two of the masters in the world of hip surgery. In 2006, Dr Jeff Mast, one of my mentors and an internationally known hip surgeon, decided to learn this approach from Dr Joel Matta, one of the most recognized pioneers of the Direct Anterior Approach. As a young surgeon, I had the rare privilege to tag along to watch and learn. With the assistance of Dr Mast and my former partner, Dr John Perry, we collaboratively performed the first Direct Anterior Hip Replacement at Mammoth Hospital in the Spring of 2006. Between that time and 2008, I read, practiced in cadaver labs and travelled within the United States and Europe to learn and master this technique. Something told me that this was a better way of doing things. During this time interval, I vacillated between using the new Direct Anterior Approach and the traditional Posterior Approach based on patient size and my perceived technical difficulty that each individual patient presented. By 2009, I felt I was ready to make the leap completely. Since that time, I have been doing 100% of total hip replacements as well as Revision Hip Replacements through the Direct Anterior Approach.

As with anything in life, results improve with practice. As of this current time, after eight years of using this technique, this procedure can be done at Mammoth Hospital in approximately 75-90 minutes with 86% of patients staying in the hospital less than 24 hours. Patients leave the hospital full weight bearing with no restrictions of their movement, no braces nor night pillows and no restrictions on their activities. Patients return to work within one to two weeks and frequently, patients are skiing within a few weeks of their operation. Looking back over the

last 8 years since doing the first Direct Anterior hip, I feel fortunate that I had the opportunity to learn this more exact way of hip replacement surgery and I am glad I made the choice to take the more demanding road and make this change. Patient outcomes and satisfaction have been amazing and continue to improve. These successes are well worth the extra time and effort that was required to learn this difficult technique.

What makes a Direct Anterior Approach Better than a Traditional Posterior Approach

1. **Smaller Incisions.** The Direct Anterior approach is done thru a 8 cm incision (3.25 inches) as opposed to a posterior approach which is almost twice as long.
2. **The Traditional Posterior Approach** occurs over the buttocks which has led to many male patients being unable to sit with a wallet in their back pocket.
3. **The Direct Anterior approach** cuts no muscles. The dissection proceeds between muscle layer intervals. This leads to no loss in power and decreased recovery time as opposed to the Traditional Posterior Approach. The older Posterior approach, by definition, splits the Gluteus Maximus muscle belly and cuts the Piriformis and short external rotator muscles off of their bony attachments. These detached and split muscles take time to repair. This adds to overall increased recovery time incurred by the Traditional Posterior Approach.
4. **The Direct Anterior Approach** occurs with the patient lying flat on their back (supine position) allowing easier airway management for the Anesthesiologist. The Traditional Posterior Approach occurs with the patient lying on their side making airway management more challenging.
5. **The Direct Anterior Approach** allows the surgeon to look directly at the acetabulum making placement of the acetabular component easier and more anatomic. When performing the Traditional Posterior Approach, the surgeon is most times operating from the patients backside looking over the front of the patient thus making visualization of the 360 degree circumference of the acetabulum difficult, if not impossible. This may distort acetabular component placement and make it less than anatomic.

6. Most importantly, due to the supine position of the patient in the Direct Anterior Approach, the pelvis can be made symmetric on the table and intraoperative fluoroscopy (live x ray) can be accurately used to place components within +/- 1mm or +/- 1 degree of perfect anatomic position (angles and measurements described in next section). This can occur in a very reproducible fashion thus decreasing the overall incidence of leg length discrepancies as compared to the traditional posterior approach .
7. This Fluoroscopic guidance in the Direct Anterior Approach allows components to be perfectly placed which adds to overall hip prosthesis stability. Traditional Posterior Approach hips have a documented dislocation rate almost 4 times that of a Direct Anterior Approach.
8. The Fluoroscopic guidance allows components to be reproducibly placed within accepted angles and measurements which adds to the overall longevity of the implant. Component wear is drastically reduced and longevity increased with anatomic position. (See case example below). The Posterior Approach does not allow this degree of precision with regards to component position as the patient is lying on their side during the operation and the pelvis cannot be leveled nor made symmetric for accurate fluoroscopic guidance.

A Tale of Two Hips

When reconstructing a hip, knee, shoulder or any other joint, it is imperative to be able to restore the original anatomy to as close to perfect as humanly possible. A technique that allows the surgeon to do this accurately and reproducibly will be a technique that produces superior results. With regards to hip replacement, there are five anatomical variables which have been identified in the literature to be important to overall hip function and rapid return to normal activities. The five variables are: Acetabular Cup or Theta angle, Anterversion Angle of the Cup, Leg Length Differential, Femoral Offset and Femoral Stem Version. A brief explanation of the importance of these five variables will follow and will be demonstrated in the following case series comparison of a hip done thru the Direct Anterior Ap-

proach (Figure 1) at Mammoth Hospital versus one done thru the Traditional Posterior Approach (Figure 2) at an outside facility.

The first variable is the **Cup angle or Theta angle**. This measurement refers to the angle that the acetabular cup prosthesis is placed in relationship to the horizontal. The Orthopaedic literature notes that in order to provide good stability and minimize component wear (longevity), this cup angle should be placed within a very tight tolerance limit between 40 and 45 degrees. Recent literature indicates that closer to 40 degrees is better. Given this most recent data, the acceptable angle limit may be narrowing thus making accurate target acquisition that much more difficult for the surgeon to achieve. The cup or Theta angle in Figure 1 done thru an Direct Anterior Approach in this case is **exactly 40 degrees to the Horizontal**.

The second angle describes the relationship of the cup in three dimensional space as related to the coronal plane (an imaginary line drawn between the front and back of your head from ear to ear (like a crown). This is called the **Version of the Cup**. Does the cup point towards the front (anteverted) or towards the back (retroverted) of this imaginary coronal line. The literature indicates that in order to maximize stability and minimize component wear, the cup should be placed at 15 degrees anteverted. In the case shown below via a direct Anterior Approach, the cup is measured at **exactly 15 degrees anteverted**.

The third variable is **Leg Length**. Does the operative leg match the length of the opposite leg or is it placed shorter or longer. Due to the supine position of the patient in a Direct Anterior Approach, a very exact measurement can be made of leg lengths thru the use of intraoperative flouroscopy. In this case, via an direct Anterior Approach, the leg length differential between legs is **+1mm longer on the operative leg as compared to the non operative leg**. This minute difference may be clinically of no consequence or may be a goal for future improvement.

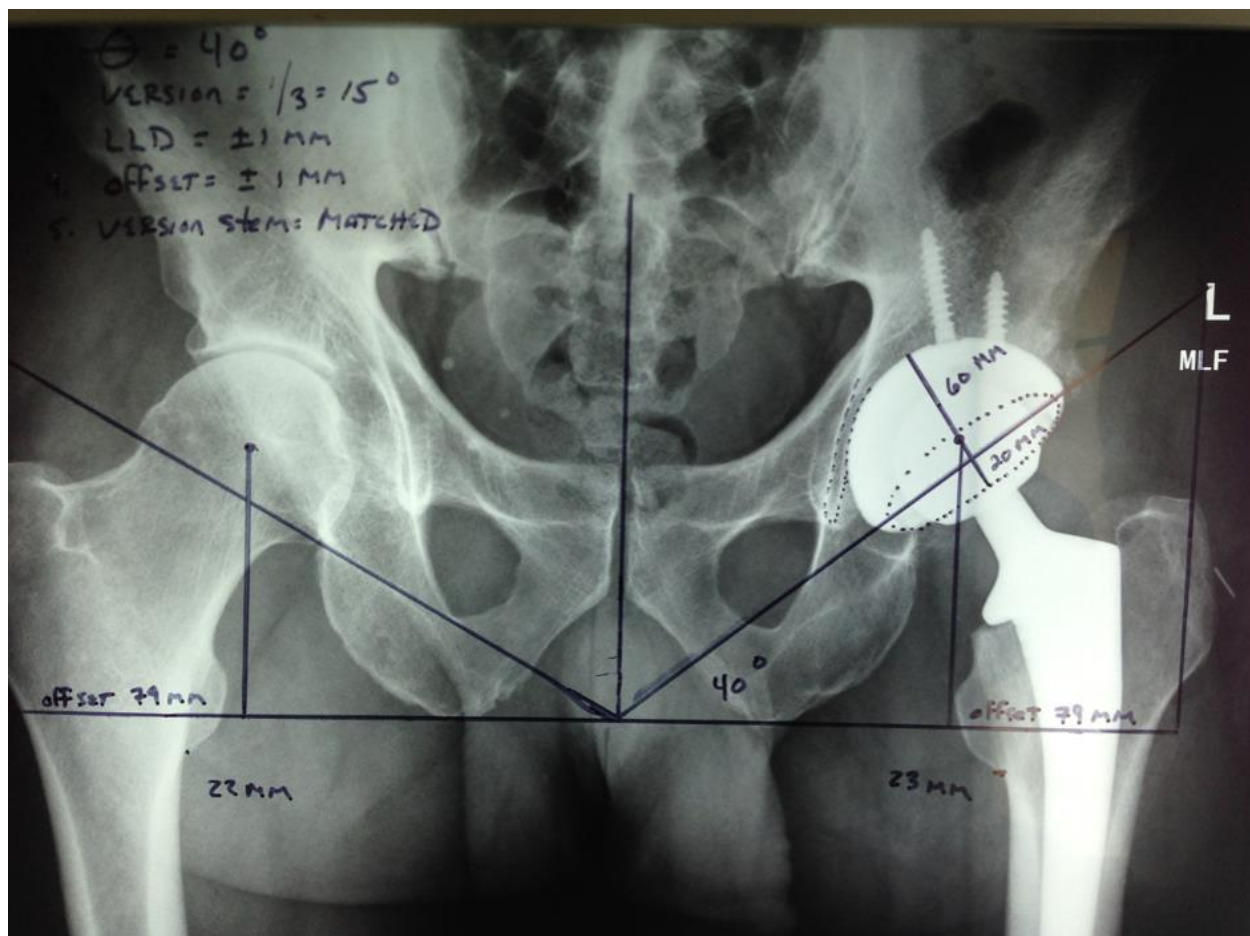
The fourth variable is **Femoral Offset**. Offset represents the distance between the center of the femoral head ball to the tip of the greater trochanter where the important hip abductor muscles attach. If this offset distance is too long, the hip is

stiff and painful due to increased tension placed on the hip abductor muscles. If the femoral offset is too short, the lever arms (muscles) within the hip are placed on slack and the hip is weak with regards to power and/or may dislocate as the hip prosthesis is not a stable construct. In the case presented below that was performed via a Direct Anterior Approach, the femoral offset on the right is 79 mm and the femoral offset on the left is also 79 mm, **representing a perfect anatomic balance between the two hips.**

The fifth variable is the orientation or **Version of the Stem** in three dimensional space again as compared to the coronal plane or imaginary line drawn from ear to ear. This stem should be placed at 15 degrees of anteversion (angled towards the front). In this case study via a Direct Anterior Approach, the version of the stem is **exactly 15 degrees anteverted.**

Figure 1: Direct Anterior Approach

When, and only when, all five variables have been achieved, the result is a stable,



painless hip that can produce power, has a full range of motion and does not dislocate. More importantly, when all the components are placed within tightly accepted tolerances (+/- 1 mm or +/- 1 degree from perfect), the hip components wear less and last longer.

In order to further the quest of perfect hip prosthetic placement, Mammoth Hospital will be introducing RadLink Technology starting in November 2014. This innovative computer software, invented in Southern California and designed specifically for the new Direct Anterior approach, interfaces with the intraoperative fluoroscopic unit and computes the five angles and measurements for the surgeon in an exact and reproducible fashion. With this cutting edge software, human error can be eliminated and exact hip prosthetics can be placed, reproducibly, time after time.

Case #2 below shows what can happen due to inaccuracies in measurement thru a Traditional Posterior Approach. This patient is a 60 year old female with end stage arthritis of the hip. Her hip was replaced at an outside facility. In her post operative period, she dislocated twice, had multiple instability episodes, was 2 cm short on the operative side, required a 1 inch shoe lift for balance and had notable hip pain on the side of her hip. Post operative X-rays show a hip prosthesis that was improperly placed in four(*) out of the five anatomic variables. This hip was revised at Mammoth Hospital with a successful outcome via a Direct Anterior Approach and thru a 3 inch incision. This minimally invasive revision technique is opposed to the original 8 inch incision on the backside from the original Traditional Posterior Approach operation.

Below: 4/5 measurements outside the accepted target range

1. (*) Cup (theta) angle: 63 degrees - (accepted range 40-45)
2. (*)Anteversion angle: 0 degrees - (Accepted target 15 degrees anteverted)
3. (*)Leg length discrepancy :19 mm longer on right - (Accepted maximum 5 mm)

4. (*)Femoral Offset Difference Left Versus Right: +13mm (Accepted difference 0mm)
5. Femoral Anteversion: 15 degrees - (Accepted target : 15 degrees)

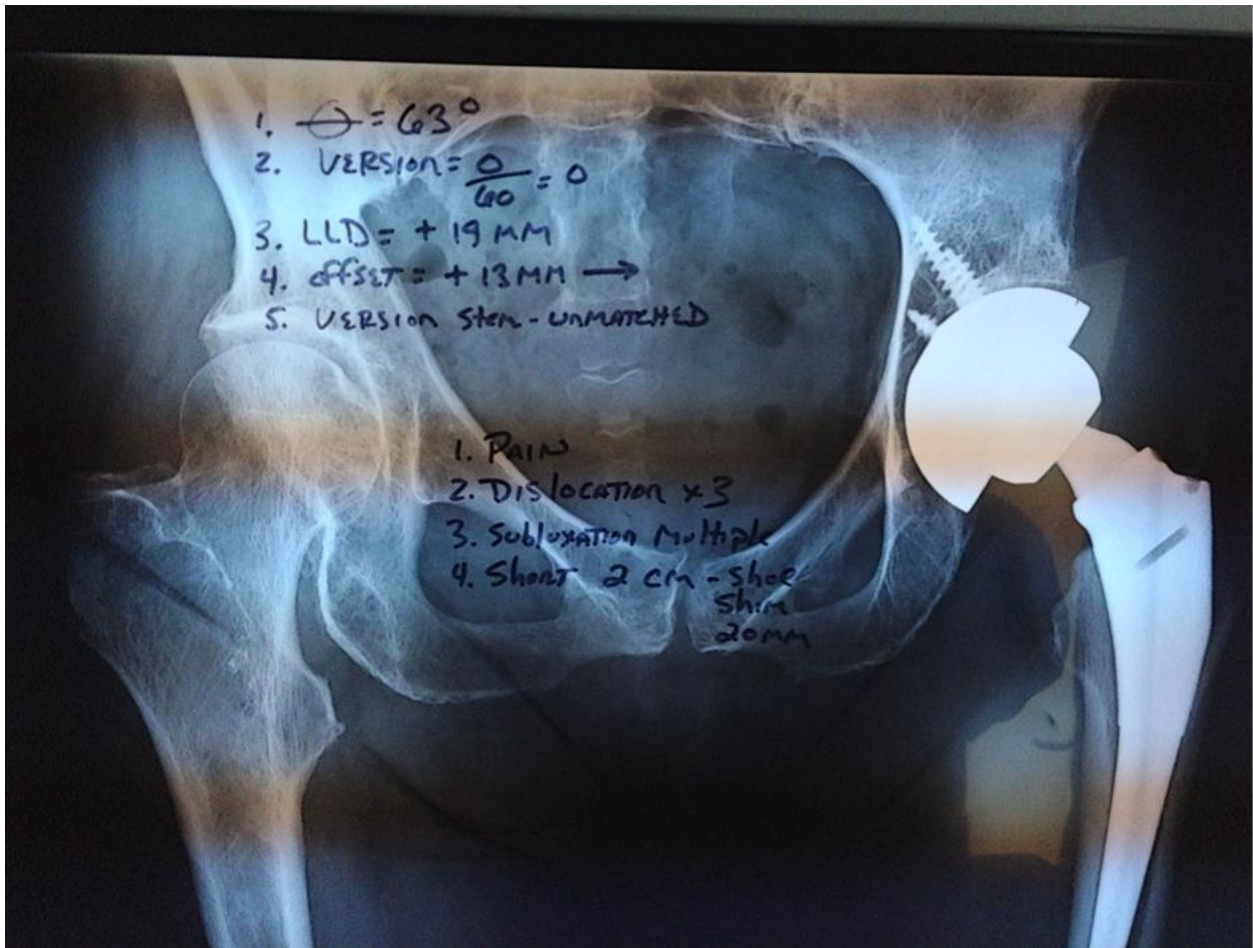


Figure 2: Traditional Posterior Approach

This is an unfortunate case but a good learning lesson for those of us that perform hip arthroplasty, irregardless of chosen approach. Anatomic position of the components is critically important to functional outcome and prosthetic longevity.

Let me be clear on one point when comparing these two case studies: It is not to say that this kind of measurement error and patient dissatisfaction seen in Figure #2 occurs all the time thru a Traditional Posterior Approach. Over the years, many successful hip replacements have been done thru the traditional approach which is a credit to the surgeons that have performed them. Rather, it should be stated that the kind of measurement exactness and patient satisfaction displayed in Figure #1 can occur every time when utilizing a Direct Anterior Approach. The Direct Anterior approach confers reproducibility in measurement and component placement both of which have been correlated to functional outcomes and prosthetic longevity.

Trying something new in life that is outside ones' comfort zone is always intimidating. Some of us are willing to make a leap and some of us will never jump. Most times, however, if one is able to overcome the personal and public criticism of breaking out of the mold, the efforts pay off exponentially. As intimidating as trying a new procedure such as the Direct Anterior Approach Hip Replacement may be for a surgeon in practice, it is always exciting and invigorating to be doing something that is new and cutting edge. This is especially rewarding when the results of the new way are dramatically improved from more traditional procedures. As a caregiver, the rewards are magnified when your personal efforts positively affect the quality of anothers' life. In the United States, about 10-20% of Orthopaedic Surgeons have adopted this New Direct Anterior Approach for our hip patients. This is a small and tightly knit group. What is common amongst this group is that we all truly believe this a better way of doing things; a more exact way, a reproducible way that is well worth the extra effort.

The Orthopaedic Surgical Team at Mammoth Hospital has been performing Direct Anterior Total Hip Arthroplasties with continued success since 2006 and will continue to push this innovative envelope under the direction of Board Certified Orthopedic Surgeon, Michael M. Karch, MD the first week of every month. Ap-

pointments can be made with Dr. Karch at (760) 924 4084 at either the Bishop, Lone Pine, or Mammoth Orthopaedic Surgery Clinic locations.
